

## PennHIP Report

Referring Veterinarian: Dr Eddy Suchy

Clinic Name: Willamette Valley Animal  
Hospital of Gladstone

Email: gladstone@wvah.net

Clinic Address: 18321 SE McLoughlin Blvd  
Milwaukie, OR 97267

Phone:

Fax:

## Patient Information

Client: Koertge, Jason

Tattoo Num:

Patient Name: Gritty

Patient ID: 177551

Reg. Name: RJ's Gritty

Registration Num: GR-012092

PennHIP Num: 202730

Microchip Num: 982091068997334

Species: Canine

Breed: WIREHAIRD POINTING GRIFFON

Date of Birth: 07 Feb 2022

Age: 27 months

Sex: Male

Weight: 60.1 lbs/27.3 kgs

Date of Study: 28 May 2024

Date Submitted: 30 May 2024

Date of Report: 04 Jun 2024

## Findings

Distraction Index (DI): Right DI = 0.36, Left DI = 0.38.

Osteoarthritis (OA): **No radiographic evidence of OA for either hip.**

Cavitation/Other Findings: No cavitation present.

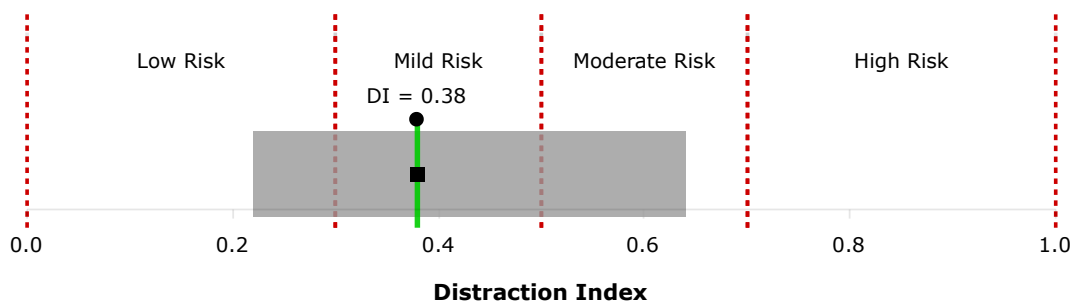
## Interpretation

Distraction Index (DI): The laxity ranking is based on the hip with the greater laxity (larger DI). In this case the DI used is 0.38.

OA Risk Category: The DI is between 0.31 and 0.49. This patient is at mild risk for hip OA.

Distraction Index Chart:

### WIREHAIRD POINTING GRIFFON



**BREED STATISTICS:** This interpretation is based on a cross-section of 1259 canine patients of the WIREHAIRD POINTING GRIFFON breed in the AIS PennHIP database. The gray strip represents the central 90% range of DIs (0.22 - 0.64) for the breed. The breed average DI is 0.38 (solid square). The patient DI is the solid circle (0.38).

**SUMMARY:** The degree of laxity (DI = 0.38) falls within the central 90% range of DIs for the breed. This amount of hip laxity places the hip at a mild risk to develop hip OA. **No radiographic evidence of OA for either hip.**

